



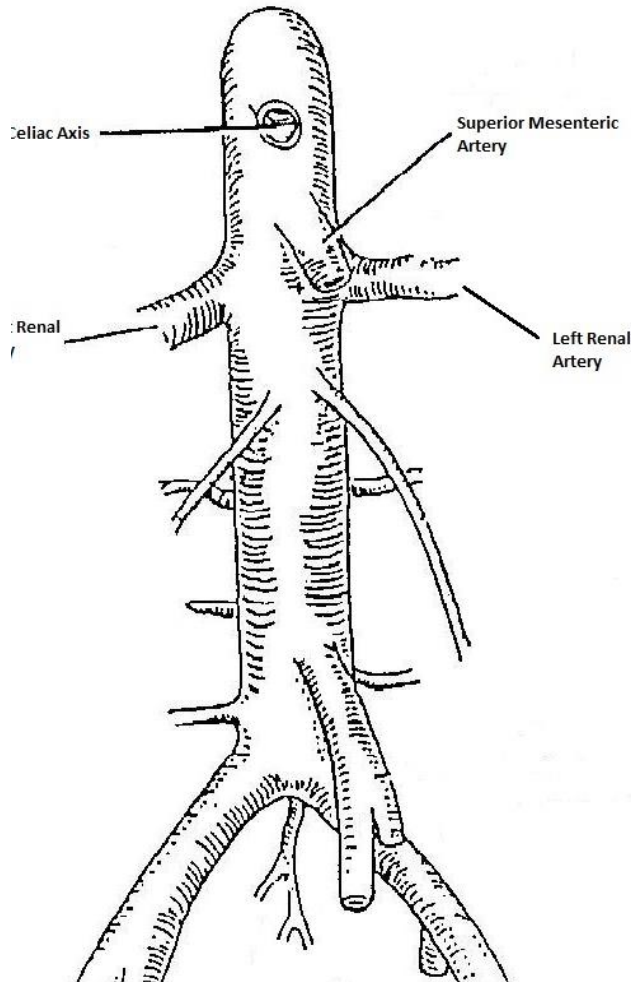
CARDIORISK AAA SCREENING

Patient Name: CARMEN, JAMES Date: 12-08-2023

DOB: 09/30/1952 Sex: M

Referring Provider: NISHANT MAGAR

Vascular Technician: MICHELE WALTERS



Aorta Prox

2.8 cm Trans X 3.0 cm AP

Aorta Mid

2.2 cm Trans X 2.2 cm AP

Aorta Distal

2.1 cm Trans X 2.1 cm AP

Comments: No Abdominal Aortic Dilatation / Aneurysm was identified in the submitted images. There was no plaque identified in the submitted images. Proximal abdominal aorta measures at the upper limits of normal. Suggest continued surveillance of the abdominal aorta to evaluate for any increasing diameter over time.



